

# *Thyroid alar cartilage (TAC) laryngotracheal reconstruction for severe pediatric subglottic stenosis\**

## ABSTRACT

**PURPOSE:** Laryngotracheoplasty has become an accepted treatment alternative for subglottic stenosis. However, the best autogenous material for laryngotracheoplasty remains controversial. Autogenous superior thyroid alar cartilage (TAC) has been successfully used in single stage laryngotracheal reconstruction in children with subglottic stenosis.

**METHODS:** This is a retrospective study of 6 children (mean age 16.6 months) undergoing TAC graft laryngotracheoplasty between September, 1995, and June, 1999. Two children had immediate tracheal intubation for congenital subglottic stenosis. Four others had previous tracheostomy: 3 for severe postintubation subglottic stenosis and 1 for congenital subglottic stenosis. After an anterior cricoid split, a piece of TAC was sutured between the cut ends of the cricoid, with the graft perichondrium facing intraluminally. Endotracheal intubation was maintained postoperatively.

**RESULTS:** Four children were successfully extubated 9 to 21 days (mean 15.5 days) postoperatively. Two required tracheostomy, which was maintained due to severe laryngomalacia and laryngotracheobronchomalacia. One child was treated with CO<sub>2</sub> laser due to symptomatic recurrence of the subglottic stenosis 3 weeks after the surgery; another required fundoplication for gastroesophageal reflux 12 months after laryngotracheoplasty. There were no donor site complications in any of the six cases. Repeat laryngoscopy and bronchoscopy revealed a patent subglottic airway. All of them are without symptoms after a mean follow-up of 26 months.

**CONCLUSIONS:** 1) This preliminary experience indicates that the TAC graft technique is a viable option for laryngotracheal reconstruction; 2) the TAC graft has significant advantages, including a single operative incision and absence of donor-site morbidity.

**INDEX WORDS:** Laryngotracheoplasty, thyroid alar cartilage graft, subglottic stenosis.

**JOSÉ CARLOS FRAGA** – Associate Professor of Pediatric Surgery, School of Medicine, and Graduate Program in Medicine: Surgery, Universidade Federal do Rio Grande do Sul; Staff Pediatric Surgery, Hospital de Clínicas de Porto Alegre, Rio Grande do Sul, Brazil.

**LUCIANO SCHOPF** – Pediatric Surgeon; Graduate Student, Graduate Program in Medicine: Surgery (MSc).

**VITO FORTE** – Associate Professor, Department of Otolaryngology, University of Toronto; Staff Otolaryngologist, Hospital for Sick Children, Toronto, Ontario, Canada.

✉ Endereço para correspondência:

**Dr. José Carlos Fraga**

Rua Ramiro Barcelos 2350, sala 600  
90430-000 – Porto Alegre – RS – Brazil

✉ jcfraga@conex.com.br

☎ +55-51-316-8232

\* Presented at the 2000 Annual Meeting of the section on surgery of the American Academy of Pediatrics, Chicago, October 2000 and published out Journal of Pediatric Surgery, August 2001.

the subglottic region; grade III – obstruction of more than 90% of the lumen, but with some visible orifice; grade IV – complete obstruction.

A longitudinal incision was performed through the anterior cricoid cartilage and was extended inferiorly into the tracheal ring(s) (Figure 1A). The stenotic region was assessed to determine the size of the graft required to cover the laryngotracheofissure. No tissue was removed from the stenotic site. A nasotracheal tube of adequate caliber was then carefully inserted and fixed. In children with previous tracheostomy, the tracheocutaneous fistula was removed and the tracheal wall in the orifice was sutured (5-0 PDS). From then on, ventilation was performed only through the nasotracheal tube.

The TAC was exposed and the size of the graft to be removed was determined (Figure 1A). The cartilage graft along with the external perichondrium was then removed leaving the internal perichondrium in situ (Figure 1C). The graft was carved and sutured into position with 5-0 PDS with the perichon-

Laryngotracheoplasty (LTP) is still the procedure of choice in children for the repair of symptomatic subglottic stenosis (1). In LTP, the diameter of the laryngotracheal complex is usually augmented with a cartilage interposition graft placed through a longitudinal incision in the cricoid cartilage (anterior and/or posterior) and in the upper tracheal ring(s). LTP may be performed as a one stage procedure (tracheal intubation for a short period) or in several stages (with tracheostomy and/or stent).

Costal and auricular cartilages are the most common tissues employed in LTP. The utilization of the superior (alar) portion of the thyroid cartilage for one-stage LTP has been recently described by one of the authors (VF) (2,3).

The objective of the present work is to describe our experience with TAC laryngotracheoplasty in chil-

dren with a diagnosis of severe subglottic stenosis.

## **P**ATIENTS AND METHODS

TAC laryngotracheoplasty was performed on six children with severe subglottic stenosis at the Hospital de Clínicas de Porto Alegre (a teaching hospital in southern Brazil) in the period from September, 1995, to June, 1999 (Table 1). Mean age was 16.6 months (ranging from 16 days to 28 months). Two children were intubated due to congenital subglottic stenosis. Four had a tracheostomy, 3 due to severe postintubation subglottic stenosis and 1 due to congenital subglottic stenosis.

The stenosis was graded following the criteria of Cotton (6): grade I – obstruction of less than 70% of the lumen; grade II – obstruction of 70 to 90% of

**Table 1** – Age, type of stenosis, and need for tracheostomy in children submitted to laryngotracheoplasty with thyroid cartilage

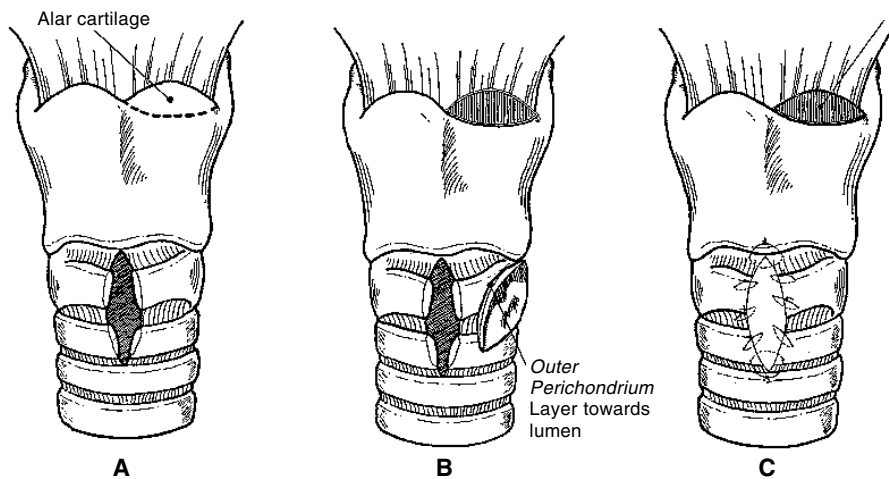
Case	Age at surgery	Etiology of stenosis	Site/Severity of stenosis	Previous tracheostomy
1	16 days	Congenital	Posterior/grade II	No
2	19 months	Postintubation	Circular/grade II	Yes
3	18 months	Postintubation	Anterior/grade II	Yes
4	18 days	Congenital	Circular/grade III	No
5	16 months	Congenital	Circular/grade III	Yes
6	28 months	Postintubation	Circular/grade III	Yes

dren in the series, extubation was attempted sooner. Extubation was performed under systemic steroid cover (dexamethasone 1 mg/kg/day) initiated 48 hours prior to extubation, and was usually maintained for 2 to 3 days following extubation.

## RESULTS

The TAC laryngotracheal reconstruction was well-tolerated. There were no complications at the donor site. Results are shown in Table 2.

Four children (67%) were successfully extubated 9 to 21 days after the procedure (mean 15.5 days). One child had a small residual stenotic segment in the subglottic region (15% of the lumen) at extubation and is asymptomatic after more than 4 years of follow-up. Another child experienced airway difficulties 3 weeks after surgery. The CO<sub>2</sub> laser was used to resect a small subglottic stenotic web, with no need for reintubation. This child is asymptomatic after 1 year of follow-up. During the late follow-up period, two other children required surgical treatments not directly related to the TAC laryngotracheoplasty: one required surgery for GER and the other required surgical closure of the tracheocutaneous fistula at the tracheostomy site. All these children have a normal voice.



**Figure 1** – Laryngotracheoplasty with thyroid alar cartilage. A) laryngotracheofissure and preparation of alar portion of thyroid cartilage; B) Removal of and placement of cartilage in fissure, taking care to keep a portion of the perichondrium internally; C) Final view after the suture. Note that the internal portion of the perichondrium is preserved at the cartilage removal site.

drium turned intraluminally (Figure 1B). A small Penrose drain was placed.

All the children received prophylactic antibiotic therapy for 24

hours. Extubation was performed initially 2 to 3 weeks after laryngotracheoplasty under endoscopic visualization in all cases. However, in the last chil-

**Table 2** – Type of surgery, intubation time, and follow-up of children with subglottic stenosis submitted to laryngotracheoplasty with thyroid cartilage

Case	Thyroid cartilage	Extubation	Postoperative endoscopy on extubation	Other procedures	Current status (follow-up)
1	Right alar	21 days	Mild laryngomalacia Patent subglottic region	Fundoplicature for GER + gastrostomy	Asymptomatic Normal voice (4 yr 9 mo)
2	Right alar	21 days	Small residual subglottic stenosis (15%)	–	Asymptomatic, normal voice (4 yr 7 mo)
3	Left alar	11 days	Patent subglottic region	–	Asymptomatic, normal voice (3 yr 5 mo)
4	Right alar	Tracheostomy	Laryngotracheobronchomalacia Patent subglottic region	Arytenoid resection	Tracheostomy (2 yr 4 mo)
5	Bilateral	Tracheostomy	Laryngomalacia Edema + supraglottic granulation Patent subglottic region	Arytenoid resection	Tracheostomy (1 yr 6 mo)
6	Right alar	9 days	Patent subglottic region	Laser resection of residual stenosis	Asymptomatic Normal voice (1 yr 1 mo)

Two children (33%) could not be extubated, and a tracheostomy was performed. One had severe laryngotracheobronchomalacia and the other laryngomalacia and edema, with granulation tissue in the supraglottic region. Both had no subglottic pathology at the graft site and have undergone endoscopic surgery for the laryngomalacia.

## **D**ISCUSSION

During the past 30 years, LTP has been the treatment of choice in children with severe subglottic stenosis. Even though LTP is indeed the procedure of choice in children with severe subglottic stenosis, the best interposition material is still controversial. Several types of materials have been described: nasal septum (4), auricular cartilage (5), costal cartilage (6), thyroid cartilage (7) and hyoid bone (8). Regardless of the type of material employed, it is important to ensure that the graft will be capable of surviving and growing.

Costal cartilage has been the most common tissues employed successfully in LTP. However, donor site morbidity and an increase in operative time are important considerations when deciding on a donor site. The use of thyroid cartilage as a graft in LTP is not new (9). However, the employment of the superior (alar) portion of the thyroid cartilage in one-stage LTP was only recently introduced by one of the authors (VF). The same authors reported an experimental study comparing the application of costal, auricular, and thyroid cartilage in LTP, and observed that the results obtained with thyroid cartilage were similar to the results achieved with the other tissues (2). Therefore thyroid cartilage seems to be good alternative for laryngotracheal reconstruction. However, despite these promising results, until the present moment there were no reports of this surgical technique in children with documented severe subglottic stenosis.

Our study describes children with severe subglottic stenosis (grades II and III), with and without tracheostomy, who underwent a one-stage TAC laryngotracheoplasty. Correction of complete obstruction of the subglottic region (grade IV stenosis) usually requires a staged procedure with prolonged stenting and tracheostomy or cricotracheal resection (10).

At the beginning of our study, we waited 3 weeks before attempting extubation. However, after the accidental extubation of one of our children on the 11th postoperative day, without any signs of obstruction, we felt encouraged to try extubation earlier. Our last patient was extubated 9 days after the procedure. We prefer to perform an endoscopic evaluation of the airway prior to extubation rather than rely on other pre-extubation criteria, such as an endotracheal tube air-leak test.

The use of thyroid cartilage graft has advantages over other types of cartilage grafts. The thickness of the thyroid alar cartilage is almost identical to that of the cricoid cartilage and requires less carving. The graft is harvested through the same incision used to expose the cricoid cartilage, eliminating the need for a second surgical incision. In our study we did not observe any complications at the donor site (mean follow-up = 26 months).

Changes in laryngeal stability have been observed in laryngotracheoplasty with any type of cartilage (1). The most commonly described changes are prolapse of supraglottic structures (arytenoid and epiglottis). The worsening of the laryngomalacia observed in our patients may have been associated with thyroid cartilage laryngotracheoplasty. However, this type of complication was not observed in experimental studies (3). Cases of significant prolapse usually improve after endoscopic resection of the redundant supraglottic tissue (1).

Removal of the superior portion of the thyroid cartilage does not affect the

growth of the larynx (3). It is likely that the preservation of the internal perichondrium at the donor site induces the formation of neocartilage, promoting regeneration (3).

We have found that the use of TAC for laryngotracheal reconstruction is a viable alternative in children with severe subglottic stenosis.

## **R**EFERENCES

1. COTTON RT. Management of subglottic stenosis. In: Jong AL, Kuppersmith RB: Update on the Pediatric Airway. *Otolaryngol Clin North Am* 33(1):111-30, 2000.
2. JONG AL, PARK A, RAVEH E, SCHWARTZ MR, FORTE V. Comparison of thyroid, auricular, and costal cartilage donor sites for laryngotracheal reconstruction in an animal model. *Arch Otolaryngol Head Neck Surg* 126:49-53, 2000.
3. PARK AH, FORTE V. The effects of harvesting autogenous cartilage for laryngotracheal reconstruction on laryngeal growth and support. *Laryngoscope* 109 (2 pt 1):307-311, 1999.
4. DRETTNER B, LINDOHL MCE. Experimental tracheal reconstruction with compositive graft from nasal septum. *Acta Otolaryngol* 70:401-407, 1970.
5. MORGENSTEIN KM. Compositive auricular graft in laryngeal reconstruction. *Laryngoscope* 82:844-847, 1972.
6. COTTON RT. The problem of pediatric laryngotracheal stenosis: a clinical and experimental study on the efficacy of autogenous cartilaginous grafts placed between the vertically divided valves of the posterior lamina of the cricoid cartilage. *Laryngoscope* 101 (Suppl 56): 1-34, 1991.
7. FEARON B, COTTON R. Subglottic stenosis in infants and children: the clinical problem and experimental surgical correction. *Can J Otolaryngol* 1:281-289, 1972.
8. FINNEGAN DA, WONG ML, KASHIMA HK. Hyoid autograft repair of chronic subglottic stenosis. *Ann Otol Rhinol Laryngol* 84(pt 1):643-649, 1975.
9. FRY TL, FISCHER ND, PILLSBURY HC. Tracheal reconstruction with pedicle thyroid cartilage. *Laryngoscope* 95(1):60-62, 1985.
10. MONNIER P, LANG F, SAVARY M. Cricotracheal resection for pediatric subglottic stenosis. *Int J Pediatr Otorhinolaryngol* 49 (Suppl 1): S283-6, 1999.